

NOVADAQ

**SPY Fluorescence Imaging**

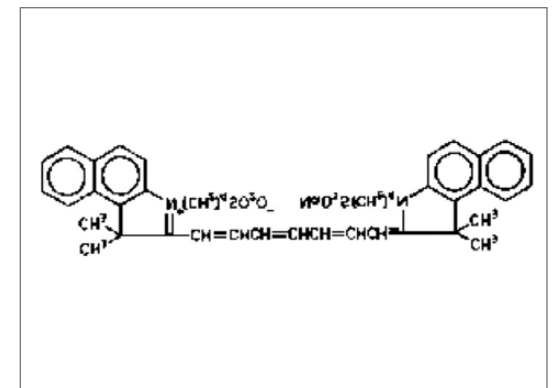
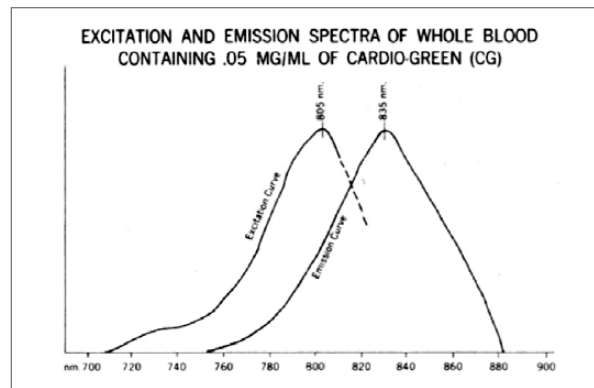
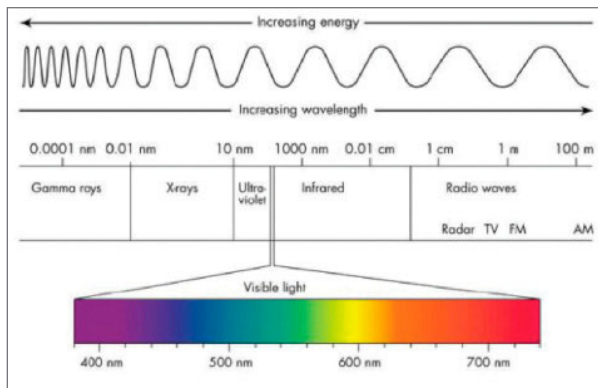
A Bibliography of Published Clinical Data,  
Abstracts, and Commentary

SPY Fluorescence Imaging was launched in the United States in 2005 by NOVADAQ within its SPY Imaging platform. Since then, this new fluorescence imaging technology for tissue perfusion has quickly become one of the most studied imaging systems in medicine. Within this document, there are more than 200 articles of published clinical data, abstracts, and commentaries. These papers demonstrate how SPY Fluorescence Imaging can be utilized across multiple applications.

Information contained in the articles, which are referenced in this bibliography, may reflect the manner in which medical devices and related products are actually used by physicians in hospitals and clinics. As you are aware, physicians, in their practice of medicine, may use medical devices and pharmaceuticals in any manner they deem to be in the best interest of their patients, even if the device or pharmaceutical is not cleared or approved by the Food and Drug Administration (FDA) for such uses. This is typically referred to as "off-label" use.

### What is SPY Fluorescence Imaging?

SPY Fluorescence Imaging utilizes laser generated, near infrared, light and Indocyanine Green (ICG) as the imaging agent. ICG has a well established safety profile and is processed through the liver and excreted within bile. Upon injection, the ICG binds to plasma proteins in the blood. The laser light source illuminates the surgical field with white light and low intensity, invisible, infrared light, causing the ICG to fluoresce. The camera system detects the fluorescing ICG as it passes through the arterial, capillary and venous phases of perfusion.



SPY Fluorescence Imaging is the primary technology in the SPY Elite System, PINPOINT Endoscopic Fluorescence Imaging System, LUNA Fluorescence Imaging System, and Firefly Fluorescence Imaging System (da Vinci Si Surgical System). The indicated uses for these devices are perfusion assessment in cardiac surgery, plastic and reconstructive surgery, open and minimally invasive gastrointestinal surgery and wound assessment.

NOVADAQ does not promote any off-label use that may be discussed in any of the articles referenced in this bibliography.

### Preface:

Please note that the materials contained in this bibliography are for informational and educational purposes only.

## Bibliography

### SPY Technologies for Open and Minimally Invasive Imaging December 2016

---

#### Cardio-Thoracic Surgery

1. Rubens FD, Ruel M, Fremes SE. A New and Simplified Method for Coronary and Graft Imaging During CABG. *The Heart Surgery Forum* 2002; 5(2):141-144.
2. Vogt PR, Bauer EP, Graves K. Novadaq Spy™ Intraoperative Imaging System—Current Status. *Thoracic Cardiovascular Surgery* 2003; 51(1):49-51.
3. Tian G, Xiang B, Dai G, Sun J, Docherty J, Mangat R, Salerno TA, Deslauriers R. Myocardial Perfusion During Simultaneous Antegrade/Retrograde Cardioplegia. *Cardiovascular Engineering* 2003; 8(1/2):50-57.
4. Taggart DP, Choudhary B, Anastasiadis K, Abu-Omar Y, Balacumaraswami L, Pigott DW. Preliminary Experience with a Novel Intraoperative Fluorescence Imaging Technique to Evaluate the Patency of Bypass Grafts in Total Arterial Revascularization. *Annals of Thoracic Surgery* 2003; 75:870-873.
5. Reuthebuch OT, Kadner A, Lachat ML, Turina MI. Graft Occlusion After Deployment of the Symmetry Bypass System. *Annals of Thoracic Surgery* 2003; 75(5):1626-1629.
6. Coles C, Taggart D, Choudhary B, Abu-Omar Y, Balacumaraswami L, Pigott D. The use of a novel imaging technique to evaluate patency of coronary grafts. *Anaesthesia* 2003; 58:304.
7. Takahashi M, Ishikawa T, Higashidani K, Katoh H. SPY™: an innovative intra-operative imaging system to evaluate graft patency during off-pump coronary artery bypass grafting; *Interactive Cardiovascular and Thoracic Surgery* 2004; 3:479-483.
8. Reuthebuch O, Kadner A, Lachat M, Kunzli A, Schurr UP, Turina MI. Early bypass occlusion after deployment of nitinol connector devices. *The Journal of Thoracic and Cardiovascular Surgery* 2004; 127(5):1421-1426.
9. Reuthebuch O, Haeussler A, Genoni M, Tavakoli R, Odavic D, Kadner A, Turina M. Novadaq Spy\* Intraoperative Quality Assessment in Off-Pump Coronary Artery Bypass Grafting. *Chest* 2004; 125:418-424.
10. Balacumaraswami L, Taggart DP. Digital Tools to Facilitate Intraoperative Coronary Artery Bypass Graft Patency Assessment; *Seminars in Thoracic and Cardiovascular Surgery* 2004; 16(3):266-271.
11. Balacumaraswami L, Abu-Omar Y, Anastasiadis K, Choudhary B, Pigott D, Yeong SK, Taggart DP. Does off-pump total arterial grafting increase the incidence of intraoperative graft failure? *The Journal of Thoracic and Cardiovascular Surgery* 2004; 238-244.
12. Yasuda T, Watanabe G, Tomita S. Transaortic injection technique in fluorescence imaging: Novel intraoperative assessment of anastomosis in off-pump coronary artery bypass grafting. *The Journal of Thoracic and Cardiovascular Surgery* 2005; 130(2):560-561.
13. Desai ND, Miwa S, Kodama D, Cohen G, Christakis GT, Goldman BS, Baerlocher MO, Pelletier MP, Fremes SE. Improving the Quality of Coronary Bypass Surgery with Intraoperative Angiography. *Journal of the American College of Cardiology* 2005; 46(8):1521-1525.
14. Balacumaraswami L, Abu-Omar Y, Choudhary B, Pigott D, Taggart DP. A comparison of transit-time flowmetry and intraoperative fluorescence imaging for assessing coronary artery bypass graft patency. *The Journal of Thoracic and Cardiovascular Surgery* 2005; 130(2):315-320.
15. Desai ND, Miwa S, Kodama D, Koyama T, Cohen G, Pelletier MP, Cohen EA, Christakis GT, Goldman BS, Fremes SE. A randomized comparison of intraoperative indocyanine green angiography and transit-time flow measurement to detect technical errors in coronary bypass grafts. *The Journal of Thoracic and Cardiovascular Surgery* 2006; 132(3):585-594.
16. Balacumaraswami L, Taggart D. Intraoperative Imaging Techniques to Assess Coronary Artery Bypass Graft Patency. *Annals of Thoracic Surgery* 2007; 83(6):2251-2257.
17. Waseda K, Ako J, Hasegawa T, Shimada Y, Ikeno F, Ishikawa T, Demura Y, Hatada K, Yock PG, Honda Y, Fitzgerald PJ, Takahashi M. Intraoperative Fluorescence Imaging System for On-Site Assessment of Off-Pump Coronary Artery Bypass Graft. *JACC: Cardiovascular Imaging* 2009; 2(5):604-612

18. Taggart DP, Balacumaraswami L, Venkatapathy A. Radial Artery Jump Graft from Anterior to Posterior Descending Coronary Artery. *Asian Cardiovascular & Thoracic Annals* 2009; 17(2):143-146.
19. Kogon B, Fernandez J, Kanter K, Kirshborn P, Vincent B, Maher K, Guzzetta N. The Role of Intraoperative Indocyanine Green Fluorescence Angiography in Pediatric Cardiac Surgery. *The Annals of Thoracic Surgery* 2009; 88(2):632-636.
20. Singh SK, Desai ND, Chikazawa G, Tsuneyoshi H, Vincent J, Zagorski BM, Pen V, Moussa F, Cohen GN, Christakis GT, Fremes SE. The Graft Imaging to Improve Patency (GRIIP) clinical trial results. *The Journal of Thoracic and Cardiovascular Surgery* 2010; 139(2):294-301.
21. Bir SC, Pattillo CB, Pardue S, Kolluru GK, Docherty J, Goyette D, Dvorsky P, Kevill CG. Nitrite anion stimulates ischemic arteriogenesis involving NO metabolism. *Am J Physiol Heart Circ Physiol*. 2012 Jul;303(2):H178-88. Epub 2012 May 18. PubMed PMID: 22610173.
22. Ferguson TB, Chen C, Babb JD, Efird JR, Daggubati R, Cahill JM. Fractional flow reserve-guided coronary artery bypass grafting: Can intraoperative physiologic imaging guide decision making? *J Thorac Cardiovasc Surg*. 146: 4 824-835. October 2013.
23. Pourmoghadam KK, Mills Bunnell AP, O'Brien MC, DeCampli WM. Avoiding Coronary Injury in Congenital Heart Surgery by Laser-Assisted Indocyanine Green Dye Imaging. *World J Pedi Cong Heart Surg*. Vol. 5(2) 326-329, 2014.
24. Pardolesi A, Veronesi G, Solli P, Spaggiari L. Use of indocyanine green to facilitate intersegmental plane identification during robotic anatomic segmentectomy. *J Thorac Cardiovasc Surg*. 2014; 148:737-8.

## Gastrointestinal Surgery

25. Cahill RA, Mortensen NJ. Intraoperative augmented reality for laparoscopic colorectal surgery by intraoperative near-infrared fluorescence imaging and optical coherence tomography. *Minerva Chir*. 2010 Aug;65(4):451-62. Review. PubMed PMID: 20802433.
26. Pineda C, Shelton A, Raju N, Welton M. Use of intraoperative fluorescence vascular angiography to assess intestinal perfusion in the creation of intestinal anastomoses. Abstract - 2nd Biennial Meeting of the Eurasian Colorectal Technologies Association (ECTA) Turin, Italy, 15-17 June 2011. *Tech Coloproctol* (2011) 15:215-253.
27. Cahill RA, Ris F, Mortensen NJ. Near-infrared laparoscopy for real-time intra-operative arterial and lymphatic perfusion imaging. *Colorectal Dis*. 2011 Nov;13 Suppl 7:12-7. doi: 10.1111/j.1463-1318.2011.02772.x. PubMed PMID: 22098511.
28. Sherwinter D. Transanal Near-Infrared Imaging of Colorectal Anastomotic Perfusion. *Surg Laparosc Endosc Percutan Tech*. Volume 22, Number 5, October 2012.
29. Jafari MD, Lee KH, Halabi WJ, Mills SD, Carmichael JC, Stamos MJ, Pigazzi A. The use of indocyanine green fluorescence to assess anastomotic perfusion during robotic assisted laparoscopic rectal surgery. *Surg Endosc*. Published online: 13 February 2013.
30. Pacheco PE, Hill SM, Henriques SM, Paulsen JK, Anderson RC. The novel use of intraoperative laser-induced fluorescence of indocyanine green tissue angiography for evaluation of the gastric conduit in esophageal reconstructive surgery. *Am J Surg*. 205: 349-353. March 2013.
31. Bae SU, Baek SJ, Hur H, Baik SH, Kim NK, Mon BS. Intraoperative Near Infrared Fluorescence Imaging in Robotic Low Anterior Resection: Three Case Reports. *Yonsei Med J*. Vol 54, No 4, July 2013.
32. Hellan M, Giuseppe S, Pigazzi A, Lagares-Garcia JA. The influence of fluorescence imaging on the location of bowel transection during robotic left-sided colorectal surgery. *Surg Endosc*. Published online January 3, 2014.
33. Foppa C, Denoya PI, Tarta C, Bergamaschi R. Indocyanine green fluorescent dye during bowel surgery: Are the blood supply "guessing days" over? *Tech Coloproctol*. Published online February 21, 2014.
34. Ris M, Hompes R, Cunningham C, Lindsey I, Guy R, Jones O, George B, Cahill R, Mortensen NJ. Near-infrared (NIR) perfusion angiography in minimally invasive colorectal surgery. *Surg Endosc*. Published online Feb 25, 2014.
35. Nachiappan S, Askari A, Currie A, Kennedy RH, Faiz O. Intraoperative assessment of colorectal anastomotic integrity: a systematic review. *Surg Endosc*. Published online April 10, 2014.

36. Sarkaria IS, Bains MS, Finley DJ, Adusumilli PS, Huang J, Rusch VW, Jones DR, Rizk NP. Intraoperative Near-Infrared Fluorescence Imaging as an Adjunct to Robotic-Assisted Minimally Invasive Esophagectomy. *Innovations*. Vol 9, No 5, Sept/Oct 2014.
37. Gorgun E. Novel anastomotic techniques. *Seminars in Colon and Rectal Surgery* 25 (2014) 110-116.
38. Jafari MD, Wexner SD, Martz JE, McLemore EC, Margolin DA, Sherwinter, DA, Lee SW, Senagore AJ, Phelan MJ, Stamos MJ. Perfusion Assessment in Laparoscopic Left Sided/ Anterior Resection (PILLAR II): A Multi-Institutional Study. *JACS*. Vol. 220, No. 1, January 2015.
39. Campbell C, Reames MK, Robinson M, Symanowski J, Salo JC. Conduit Vascular Evaluation is Associated with Reduction in Anastomotic Leak After Esophagectomy. *J Gastrointest Surg*. Published online 20 March 2015.
40. Protyniak B, Dinallo AM, Boyan Jr WP, Dressner RM, Arvanitis ML. Intraoperative Indocyanine Green Fluorescence Angiography – An Objective Evaluation of Anastomotic Perfusion in Colorectal Surgery. *The American Surgeon*. Vol 81. June 2015.
41. Kazanowski M, Al Furajii H, Cahill RA. Near-infrared laparoscopic fluorescence for pelvic side wall delta mapping in patients with rectal cancer – ‘PINPOINT’ nodal assessment. *Colorectal Disease*© 2015 The Association of Coloproctology of Great Britain and Ireland. 17 (Suppl. 3), 32-35.
42. Ris F, Buchs NC, Morel P, Mortensen NJ, Hompes R. Discriminatory influence of PINPOINT perfusion imaging on diversion ileostomy after laparoscopic low anterior resection. *Colorectal Disease*© 2015 The Association of Coloproctology of Great Britain and Ireland. 17 (Suppl. 3), 29-31.
43. Grone J, Koch D, Kreis ME. Impact of intraoperative microperfusion assessment with PINPOINT Perfusion Imaging on surgical management of laparoscopic low rectal and anorectal anastomoses. *Colorectal Disease*© 2015 The Association of Coloproctology of Great Britain and Ireland. 17 (Suppl. 3), 22-28.
44. James DRC, Ris F, Yeung TM, Kraus R, Buchs NC, Mortensen NJ, Hompes RJ. Fluorescence angiography in laparoscopic low rectal and anorectal anastomoses with PINPOINT perfusion imaging – a critical appraisal with specific focus on leak risk reduction. *Colorectal Disease*© 2015 The Association of Coloproctology of Great Britain and Ireland. 17 (Suppl. 3), 16-21.
45. Nowak K, Sandra-Petrescu F, Post S, Horisberger K. Ischemic and injured bowel evaluation by Fluorescence imaging. *Colorectal Disease*© 2015. The Association of Coloproctology of Great Britain and Ireland. 17 (Suppl. 3), 12-15.
46. Gossedge G, Vallance A, Jayne D. Diverse applications for near infra-red intraoperative imaging. *Colorectal Disease*© 2015 The Association of Coloproctology of Great Britain and Ireland. 17 (Suppl. 3), 7-11.
47. Fengler J. Near-infrared fluorescence laparoscopy – technical description of PINPOINT a novel and commercially available system. *Colorectal Disease*© 2015. The Association of Coloproctology of Great Britain and Ireland. 17 (Suppl. 3), 3-6.
48. Stamos MJ. Enhanced imaging. *Colorectal Disease*© 2015. The Association of Coloproctology of Great Britain and Ireland. 17 (Suppl. 3), 1-2.
49. Bae SU, Min BS, Kim NK. Robotic Low Ligation of the Inferior Mesenteric Artery for Rectal Cancer Using the Firefly Technique. *Yonsei Med J*. Vol 56, No 4, July 2015.
50. Zehetner J, DeMeester SR, Alicuben ET, Oh DS, Lipham JC, Hagen JA, DeMeester TR. Intraoperative Assessment of Perfusion of the Gastric Graft and Correlation With Anastomotic Leaks After Esophagectomy. *Ann Surg*. Vol 262, No 1, July 2015.
51. Kim JC, Lee JL, Yoon YS, Alotaibi AM, Kim J. Utility of indocyanine-green fluorescent imaging during robot-assisted sphincter-saving surgery on rectal cancer patients. *Int J Med Robotics Comput Assist Surg*. 2015.
52. Ris F, Yeung T, Hompes R, Mortensen NJ. Enhanced Reality and Intraoperative Imaging in Colorectal Surgery. *Clinics in colon and Rectal Surgery*. Vol 28, No 3/2015.
53. Kin C, Vo H, Welton L, Welton M. Equivocal Effect of Intraoperative Fluorescence Angiography of Colorectal Anastomotic Leaks. *Diseases of the Colon & Rectum*. Vol 58: 6 (2015).
54. Fikfak V, Gaur P, Kim MP. Endoscopic evaluation of gastric conduit perfusion in minimally invasive Ivor Lewis esophagectomy. *International Journal of Surgery Case Reports*. 19 (2016) 112-114.
55. Johnson EK, Hardin MO, Walker AS, Hatch Q, Steele SR. Fluorescence Angiography in Colorectal Resection. *Dis Colon Rectum* 2016; 59: e1-e4.

56. Ryu S, Yoshida M, Hironori O, Tsursui N, Suzuki N, Ito E, Nakajima K, Yanagisawa S, Kitajima M, Suzuki Y. Intraoperative ICG fluorescence contrast imaging of the main artery watershed area in colorectal cancer surgery: Report of a case. *International Journal of Surgery Case Reports*. 26 (2016) 176-178.
57. Chadi SA, Fingerhut A, Berho M, DeMeester SR, Fleshman JW, Hyman NH, Margolin DA, Martz JE, McLemore EC, Molena D, Newman MI, Rafferty JF, Safar B, Senagore AJ, Zmora O, Wexner SD. Emerging Trends in the Etiology, Prevention, and Treatment of Gastrointestinal Anastomotic Leakage. *J Gastrointest Surg*. Published online Sept. 2016.
58. Vallance A, Wexner S, Berho M, Cahill R, Coleman M, Haboubi N, Heald RJ, Kennedy RH, Moran B, Mortensen N, Motson RW, Novell R, O'Connell PR, Ris F, Rockall T, Senapati A, Windsor A, Jayne DG. A collaborative review of the current concepts and challenges of anastomotic leaks in colorectal surgery. *Colorectal Disease*. Accepted article online 27 September 2016. doi:10.1111/codi.13534
59. Mizrahi I, Wexner SD. Clinical role of fluorescence imaging in colorectal surgery – a review. *Expert Review of Medical Devices*. 2016. DOI: 10.1080/17434440.2017.1265444
60. Ryu S, Yoshida M, Ohdaira H, Tsutsui N, Suzuki N, Ito E, Nakajima K, Yanagisawa S, Kitajima M, Suzuki Y. A case of incarcerated femoral hernia with intestinal blood flow assessment by bright field full-color near-infrared fluorescence camera: Report of a case. *International Journal of Surgery Case Reports* 29 (2016) 234-236. Open Access. doi.org/10.1016/j.ijscr.2016.11.041

## General Surgery

61. Buchs NC, Hagen ME, Pugin F, Volonte F, Bucher P, Schiffer E, Morel P. Intra-operative fluorescent cholangiography using indocyanin green during robotic single site cholecystectomy. *Int J Med Robotics Comput Assist Surg*. Volume 8, Issue 4, Article first published online: 31 May 2012.
62. Wang HD, Singh DP. Case Report: The use of indocyanine green angiography to prevent wound complications in ventral hernia repair with open components separation technique. *Hernia*. 20 June 2012.
63. Sherwinter DA. Identification of Anomalous Biliary Anatomy Using Near-Infrared Cholangiography. *J Gastrointest Surg*. (2012) Jul 3, 16:1814-1815.
64. Spinoglio G, Priora F, Bianchi PP, Lucido FS, Licciardello A, Maglione V, Grosso F, Quarati R, Ravazzoni F, Lenti LM. Real-time near-infrared (NIR) fluorescent cholangiography in singlesite robotic cholecystectomy (SSRC): a single-institutional prospective study. *Surg Endosc*. 2012 Dec 28.
65. Patel KM, Bhanot P, Franklin B, Albino F, Nahabedian MY. Use of intraoperative indocyanin-green angiography to minimize wound healing complications in abdominal wall reconstruction. *J Plast Surg Hand Surg*, 2013; Early Online: 1-5 ©2013 Informa Healthcare.
66. Daskalaki D, Fernandes E, Wang X, Bianco FM, Elli EF, Ayloo S, Masrur M, Milone L, Giulianotti PC. Indocyanine Green (ICG) Fluorescent Cholangiography During Robotic Cholecystectomy: Results of 184 Consecutive Cases in a Single Institution. *Surgical Innovation*. 2014.
67. Cho J, May A, Ryan H, Tsuda S. Intraoperative use of fluorescent imaging with indocyanine green changes management of abdominal wall flaps during open ventral hernia repair *Surg Endosc* (2015)
68. Kono Y, Ishizawa T, Tani K, Harada N, Kaneko J, Saiura A, Bandai Y, Kokudo N. Techniques of Fluorescence Cholangiography During Laparoscopic Cholecystectomy for Better Delineation of the Bile Duct Anatomy. *Medicine*. Vol 94, No 25, June 2015.
69. Colavita PD, Wormer BA, Belyansky I, Lincourt A, Getz SB, Heniford BT, Augenstein VA. Intraoperative indocyanine green fluorescence angiography to predict wound complications in complex ventral hernia repair. *Hernia*. Published online: 18 August 2015.
70. Sound S, Okoh AK, Bucak E, Yigitbas H, Dural C, Berber E. Intraoperative tumor localization and tissue distinction during robotic adrenalectomy using indocyanine green fluorescence imaging: a feasibility study. *Surg Endosc*. Published online: 22 July 2015.
71. Chakedis JM, Maser C, Brumund KT, Bouvet M. Case Report – Indocyanine green fluorescence-guided redo parathyroidectomy. *BMJ*. Published 2 Sept. 2015.
72. Sound S, Okoh A, Yigitbas H, Yazici P, Berber E. Utility of Indocyanine Green Fluorescence Imaging for Intraoperative Localization in Reoperative Parathyroid Surgery. *Surgical Innovation*. 2015.
73. DeLong JC, Chakedis JM, Hosseini A, Kelly KJ, Horgan S, Bouvet M. Indocyanine Green (ICG) Fluorescence-Guided Laparoscopic Adrenalectomy. *J. Surg. Oncol*. 2015;112:650-653.
74. Fortuny JV, Belfontali V, Sadowski SM, Karenovics W, Guigard S, Triponez F. Parathyroid gland angiography with indocyanine green fluorescence to predict parathyroid function after thyroid surgery. Published online in Wiley Online Library (www.bjs.co.uk). 2016.

75. Zarrinpar A, Dutson EP, Mobley C, Busuttil RW, Lewis CE, Tillou A, Cheaito A, Hines OJ, Agopian VG, Hiyama DT. Intraoperative Laparoscopic Near-Infrared Fluorescence Cholangiography to Facilitate Anatomical Identification: When to Give Indocyanine Green and How Much. *Surgical Innovation*. 2016.
76. Tsutsui N, Yoshida M, Kitajima M, Suzuki Y. Laparoscopic cholecystectomy using the PINPOINT endoscopic fluorescence imaging system with intraoperative fluorescent imaging: A case report. *International Journal of Surgery Case Reports* 21 (2016) 129-132.
77. Fortuny JV, Karenovics W, Triponez F, Sadowski SM. Intra-Operative Indocyanine Green Angiography of the Parathyroid Gland. *World J Surg*. Published online: March 2016.
78. Zaidi N, Bucak E, Okoh A, Yazici P, Yigitbas H, Berber E. The Utility of Indocyanine Green Near Infrared Fluorescent Imaging in the Identification of Parathyroid Glands During Surgery for Primary Hyperparathyroidism. *Journal of Surgical Oncology*. Published Online 2016.
79. Zaidi N, Bucak E, Yazici P, Soundararajan S, Okoh A, Yigitbas H, Dural C, Berber E. The Feasibility of Indocyanine Green Fluorescence Imaging for Identifying and Assessing the Perfusion of Parathyroid Glands During Total Thyroidectomy. *Journal of Surgical Oncology*. Published Online 2016.
80. Wormer BA, Huntington CR, Ross SW, Colavita PD, Lincourt AE, Prasad T, Sing RF, Getz SB, Belyansky I, Heniford BT, Augenstein VA. A prospective randomized double-blinded controlled trial evaluating indocyanine green fluorescence angiography on reducing wound complications in complex abdominal wall reconstruction. *Journal of Surgical Research*. May 2016 (202) 461-472.
81. Zroback C, Chow G, Meneghetti A, Warnock G, Meloche M, Chie CJ, Panton ON. Fluorescent cholangiography in laparoscopic cholecystectomy: the initial Canadian experience. *Am J Surg*. Vol 211, No 5, May 2016.
82. Fortuny JV, Sadowski SM, Belfontali V, Karenovics W, Guigard S, Triponez F. Indocyanine Green Angiography in Subtotal Parathyroidectomy: Technique for the Function of the Parathyroid Remnant. *JACS*. Vol 223, No 5, November 2016. Open Access [doi.org/10.1016/j.jamcollsurg.2016.08.540](https://doi.org/10.1016/j.jamcollsurg.2016.08.540).
83. Ishizawa T, Saiura A, Kokudo N. Clinical application of indocyanine green-fluorescence imaging during hepatectomy. *HepatoBiliary Surg Nutr* 2016;5(4):322-328.
84. Yu HW, Chung JW, Yi JW, Song R-Y, Lee J-H, Kwon H, Kim S-J, Chai YJ, Choi JY, Lee KE. Intraoperative localization of the parathyroid glands with indocyanine green and Firefly(R) technology during BABA robotic thyroidectomy. *Surg Endosc*. Published online Nov 2016. DOI 10.1007/s00464-016-5330-y.
85. Ryu Shunjin, Yoshida M, Ohdaira H, Tsutsui N, Suzuki N, Ito E, Nakajima K, Yanagisawa S, Kitajima M, Suzuki Y. Blood flow evaluation using PINPOINT® in a case of incarcerated inguinal hernia: A case report. *Asian J Endosc Surg*. 2016. DOI: 10.1111/ases.12333.

## General Thoracic Surgery

86. Gilmore DM, Khullar OV, Colson YL. Developing intrathoracic sentinel lymph node mapping with near-infrared fluorescent imaging in non-small cell lung cancer. *J Thorac Cardiovasc Surg*. Vol 144, No 3. Sept. 2012.
87. Wagner OJ, Louie BE, Vallières E, Aye RW, Farivar AS. Near-infrared fluorescence imaging can help identify the contralateral phrenic nerve during robotic thymectomy. *Ann Thorac Surg*. 2012 Aug;94(2):622-5. doi: 10.1016/j.athoracsur.2012.04.119.
88. Gilmore DM, Khullar OV, Jaklitsch MT, Chirieac LR, Frangioni JV, Colson YL. Identification of metastatic nodal disease in a phase 1 dose-escalation trial of intraoperative sentinel lymph node mapping in non-small cell lung cancer using near-infrared imaging. *J Thorac Cardiovasc Surg*. 146: 3 562-570. September 2013.
89. Hachey KJ, Gilmore DM, Armstrong KW, Harris SE, Hornick JL, Colson YL, Wee JO. Safety and feasibility of near-infrared image-guided lymphatic mapping of regional lymph nodes in esophageal cancer. *J Thorac Cardiovasc Surg* 2016;152:546-54.
90. Li H, Zhou J, Chi C, Mao Y, Yang F, Tian J, Wang J. Clinical application of near-infrared thoracoscope with indocyanine green in video-assisted thoracoscopic bullectomy. *J Thorac Dis* 2016;8(7):1841-1845.

## Gynecology and Gynecologic Oncology Surgery

91. Rossi EC, Ivanova A, Boggess JF. Robotically assisted fluorescence-guided lymph node mapping with ICG for gynecologic malignancies: A feasibility study. *Gynecologic Oncology* 124 (2012) 78-82.

92. Holloway RW, Molero Bravo RA, Rakowski JA, James JA, Jeppson CN, Ingersoll SB, Ahmad S. Detection of sentinel lymph nodes in patients with endometrial cancer undergoing robotic-assisted staging: A comparison of colorimetric and fluorescence imaging. *Gynecologic Oncology* 126 (2012) 25-29.
93. Rossi EC, Jackson A, Ivanova A, Boggess JF. Detection of Sentinel Nodes for Endometrial Cancer With Robotic Assisted Fluorescence Imaging: Cervical Versus Hysteroscopic Injection. *International Journal of Gynecological Cancer*. Vol 23, No 9, November 2013.
94. Ansari M, Ghodsi Rad MA, Hassanzadeh M, Gholami H, Yousefi Z, Dabbagh VR, Sadeghi R. Sentinel node biopsy in endometrial cancer: Systematic review and meta-analysis of the literature. *Eur J Gynaec Oncol*. 2013.
95. Abu-Rustum NR. Sentinel Lymph Node Mapping for Endometrial Cancer: A Modern Approach to Surgical Staging. *JNCCN. Focused Review*. Vol 12 Number 2, Feb 2014.
96. Jewell EL, Huang JJ, Abu-Rustum NR, Gardner GJ, Brown CL, Sonoda Y, Barakat RR, Levine DA, Leitao MM. Detection of sentinel lymph nodes in minimally invasive surgery using indocyanine green and near-infrared fluorescence imaging for uterine and cervical malignancies. *Gynecologic Oncology* 133 (2014) 274-277.
97. Plante M, Touhami O, Trinh XB, Renaud MC, Sebastianelli A, Grondin K, Gregoire J. Sentinel node mapping with indocyanine green and endoscopic near-infrared fluorescence imaging in endometrial cancer. A pilot study and review of the literature. *Gynecologic Oncology*. 137 (2015) 443-447.
98. Guan X, Tu Anh Nguyen M, Walsh TM, Kelly B. Robotic Single-Site Endometriosis Resection Using Firefly Technology. *Journal of Minimally Invasive Gynecology*. Accepted: 8/1/2015.
99. Rajanbabu A, Venkatesan R, Chandramouli S, Nitu PV. Sentinel node detection in endometrial cancer using indocyanine green and fluorescence imaging – a case report. *ecancer* 2015, 9:549.
100. Tanner EJ, Sinno AK, Stone RL, Levinson KL, Long KC, Fader AN. Facts associated with successful bilateral sentinel lymph node mapping in endometrial cancer. *Gynecologic Oncology*. 2015.
101. How J, Gotlieb WH, Press JZ, Abitbol J, Pelmus M, Ferenczy A, Probst S, Gotlieb R, Brin S, Lau S. Comparing indocyanine green, technetium, and blue dye for sentinel lymph node mapping in endometrial cancer. *Gynecologic Oncology* 137 (2015) 436-442.
102. Darin MC, Rodriguez Gómez-Hidalgo N, Westin SN, Soliman PT, Escobar PF, Frumovitz M, Ramirez PT. Role of Indocyanine Green in Sentinel Node Mapping in Gynecologic Cancer: Is Fluorescence Imaging the New Standard?. *The Journal of Minimally Invasive Gynecology*. Vol 23, No 2, February 2016.
103. Kimmig R, Aktas B, Buderath P, Rusch P, Heubner M. Intraoperative Navigation in Robotically Assisted Compartmental Surgery of Uterine Cancer by Visualisation of Embryologically Derived Lymphatic Networks With Indocyanine-Green (ICG). *J. Surg. Oncol*. 2016.
104. Siesto G, Romano F, Fiamengo B, Vitobello D. Sentinel Node Mapping Using Indocyanine Green and Near-Infrared Fluorescence Imaging Technology for Uterine Malignancies: Preliminary Experience with the Da Vinci Xi System. *The Journal of Minimally Invasive Gynecology* (2016) 23, 470-471. doi: 10.1016/j.jmig.2015.12.013.
105. Paley PJ, Veljovich DS, Press J, Isacson C, Pizer E, Shah C. A prospective investigation of fluorescence imaging to detect sentinel lymph nodes at robotic-assisted endometrial cancer staging, *American Journal of Obstetrics and Gynecology*. 2016;215:117.e1-7.
106. Holloway RW, Gupta S, Stavitzki NM, Zhu X, Takimoto EL, Gubbi A, Bigsby GE, Brudie LA, Kendrick JE, Ahmad S. Sentinel lymph node mapping with staging lymphadenectomy for patients with endometrial cancer increases the detection of metastasis. *Gynecol Oncol*. 141 (2016) 206-210.
107. Eriksson AGZ, Montovano M, Beavis A, Soslow RA, Zhou Q, Abu-Rustum NR, Gardner GJ, Zivanovic O, Barakat RR, Brown CL, Levine DA, Sonoda Y, Leitao MM, Jewell EL. Impact of Obesity on Sentinel Lymph Node Mapping in Patients with Newly Diagnosed Uterine Cancer Undergoing Robotic Surgery. *Ann Surg Oncol*. Published online Feb 23, 2016.
108. Beavis AL, Salazar-Marioni S, Sinno AK, Stone RL, Fader AN, Santillan-Gomez A, Tanner EJ. Sentinel lymph node detection rates using indocyanine green in women with early-stage cervical cancer. *Gynecologic Oncology* 143 (2016) 302-306. doi: 10.1016/j.ygyno.2016.08.236.
109. Escobar PF, Ramirez PT, Garcia Ocasio RE, Pareja R, Zimberg S, Spargue M, Frumovitz M. Utility of indocyanine green (ICG) intra-operative angiography to determine uterine vascular perfusion at the time of radical trachelectomy. *Gynecologic Oncology*. 143 (2016) 357-361. doi:10.1016/j.ygyno.2016.08.239.

## Liver and Hepatobiliary Surgery



110. Sekijima M, Tojimbara T, Sato S, Nakamura M, Kawase T, Kai K, Urashima Y, Nakajima I, Fuchinoue S, Teraoka S. An Intraoperative Fluorescent Imaging System in Organ Transplantation. *Transplantation Proceedings* 2004; 36(7):2188-2190.
111. Kubota K, Kita J, Shimoda M, Rokkaku K, Kato M, Iso Y, Sawada T. Intraoperative assessment of reconstructed vessels in living-donor liver transplantation, using a novel fluorescence imaging technique. *Journal of Hepatobiliary Pancreatic Surgery* 2006; 13:100-104.
112. Sanchez EQ, Chinnakotla S, Khan T, Nikitin D, Vasani S, Randall HB, McKenna GJ, Ruiz R, Onaca N, Levy MF, Goldstein RM, Docherty JC, Hurd DK, Klintmalm GB. Intraoperative imaging of pancreas transplant allografts using indocyanine green with laser fluorescence. *Proceedings (Baylor University Medical Center)* 2008; 21(3):258-260.
113. Garcia-Roca R, Walczak D, Tzvetanov I, Khan A, Oberholzer J. The Application of Indocyanine Green to Evaluate Duodenal Perfusion in Pancreas Transplantation. *American Journal of Transplantation*. 14: 227-228. 2014.
114. Tanaka M, Inoue Y, Mise Y, Ishizawa T, Arita J, Takahashi Y, Saiura A. Laparoscopic deroofing for polycystic liver disease using laparoscopic fusion indocyanine green fluorescence imaging. *Surg Endosc*. Published online September 28, 2015.

## Plastic and Reconstructive Surgery

115. Tan BKH, Newman MI, Swartz KA, Samson MC. Subfascial Perforator Dissection for DIEP Flap Harvest. *Plastic and Reconstructive Surgery* 2009; 124(3):1001-1002 [Letter].
116. Pestana IA, Coan B, Erdmann D, Marcus J, Levin LS, Zenn MR. Early Experience with Fluorescent Angiography in Free-Tissue Transfer Reconstruction. *Plastic and Reconstructive Surgery* 2009; 123(4):1239-1244.
117. Newman MI, Samson MC. The Application of Laser-Assisted Indocyanine Green Fluorescent Dye Angiography in Microsurgical Breast Reconstruction. *Journal of Reconstructive Microsurgery* 2009; 25(1):21-26.
118. Murray JD, Jones GE, Elwood ET, Whitty LA, Garcia C. Fluorescent Intraoperative Tissue Angiography with Indocyanine Green: The Evaluation of Nipple-Areolar Vascularity during Breast Reduction Surgery. *Plastic and Reconstructive Surgery* 2009; 124(4 Suppl):60.
119. Jones GE, Garcia CA, Murray J, Elwood ET, Whitty LA. Fluorescent Intraoperative Tissue Angiography for the Evaluation of the Viability of Pedicled TRAM Flaps. *Plastic and Reconstructive Surgery* 2009; 124(4 Suppl):53.
120. Francisco, BS, Kerr-Valentic, MA, Agarwal, JP. Laser-Assisted Indocyanine Green Angiography and DIEP Breast Reconstruction. *Plastic and Reconstructive Surgery - Viewpoints* 2010; 125(3): 116e-118e.
121. Mohebbali J, Gottlieb LJ, Agarwal JP. Further Validation for Use of the Retrograde Limb of the Internal Mammary Vein in Deep Inferior Epigastric Perforator Flap Breast Reconstruction Using Laser-Assisted Indocyanine Green Angiography. *Journal of Reconstructive Microsurgery* 2010; 26(2):131-135.
122. Komorowska-Timek E, Gurtner GC. Intraoperative Perfusion Mapping with Laser-Assisted Indocyanine Green Imaging Can Predict and Prevent Complications in Immediate Breast Reconstruction. *Plastic and Reconstructive Surgery* 2010; 125(4):1065-1073.
123. Jones EG. *Bostwick's Plastic & Reconstructive Breast Surgery Third Edition: Technologic Advances in Breast Surgery*. Quality Medical Publishing, Inc. 2010.
124. Newman MI, Samson MC, Tamburrino JF, Swartz KA., Department of Plastic Surgery, Cleveland Clinic Florida, Intraoperative laser-assisted indocyanine green angiography for the evaluation of mastectomy flaps in immediate breast reconstruction. *J Reconstr Microsurg*. 2010 Sep;26(7):487-92. Epub 2010 Jun 10.
125. Newman MI, Samson MC, Tamburrino JF, Swartz KA, Brunworth, L. An investigation of the application of laser-assisted indocyanine green fluorescent dye angiography in pedicle transverse rectus abdominus myocutaneous breast reconstruction. *Can J Plast Surg* Vol 19 No 1 Spring 2011.
126. Brunsworth LS, Samson MC, Newman, MI, Ramirez JR. Nipple-Areola Complex Evaluation in Long Pedicled Breast Reductions with Real-Time Fluorescent Videoangiography. Vol 128 Number 2 585-587 - Letters. *Plastic and Reconstructive Surgery*. August 2011.
127. Liu DZ, Mathes DW, Zenn MR, Neligan PC. The Application of Indocyanine Green Fluorescence Angiography in Plastic Surgery. *J Reconstr Microsurg* 2011;27:355-364.
128. Zenn MR. Fluorescent Angiography. *Clin Plastic Surg* 38 (2011) 293-300.
129. Howard, RT, Valerio, IL, Basile, PL, Nesti, L. The Use of Intraoperative Fluorescent Angiography to Maximize Fasciocutaneous Flap Coverage of Battle Field Extremity Injuries.

Supplement to Plastic and Reconstructive Surgery Vol. 128, No. 4 (2011) 79-80. Abstract.

130. Woodard, CR, Most, SP. Intraoperative Angiography Using Laser-Assisted Indocyanine Green Imaging to Map Perfusion of Forehead Flaps. Arch Facial Plast Surg. Published online February 20, 2012.
131. Losken A, Zenn M, Hammel J, Walsh M, Carlson G. Assessment of Zonal Perfusion Using Intraoperative Angiography during Abdominal Flap Breast Reconstruction. Plastic and Reconstructive Surgery. Volume 129, Number 4, April 2012.
132. Phillips B, Lanier S, Conkling N, Wang E, Dagum A, Ganz J, Khan S, Bui D. Intraoperative Perfusion Techniques Can Accurately Predict Mastectomy Skin Flap Necrosis in Breast Reconstruction: Results of a Prospective Trial. Plastic and Reconstructive Surgery. Volume 129, Number 5, May 2012.
133. Moyer H, Losken A. Predicting Mastectomy Skin Flap Necrosis with Indocyanine Green Angiography: The Gray Area Defined. Plastic and Reconstructive Surgery. Volume 129, Number 5, May 2012.
134. Sacks JM, Nguyen AT, Broyles JM, Yu P, Valerio IL, Baumann DP. Near-Infrared Laser-Assisted Indocyanine Green Imaging for Optimizing the Design of the Anterolateral Thigh Flap. ePlasty. 2012;12:e30. Epub 2012 Jul 5.
135. Christensen JM, Baumann DP, Myers JN, Burett, K, Sacks, JM. Indocyanine Green Near-Infrared Laser Angiography Predicts Timing for the Division of a Forehead Flap. ePlasty. Volume 12. August 31, 2012.
136. Bank J, Pavone LA, Seitz IA, Roughton MC, Schecter LS. Case Report and Review of the Literature: Deep Inferior Epigastric Perforator Flap for Breast Reconstruction After Abdominal Recontouring. ePlasty. Volume 12. December 2012.
137. Gurtner GC, Jones GE, Neligan PC, Newman MI, Phillips BT, Sacks JM, Zenn MR. Intraoperative laser angiography using the SPY system: review of the literature and recommendations for use. Ann Surg Innov Res. 2013 Jan 7;7(1):1.
138. Shah A, Au A. Laser-Assisted Indocyanine Green Evaluation of Paramedian Forehead Flap Perfusion Prior to Pedicle Division. ePlasty. Volume 13, pgs 55-61. Feb 18, 2013.
139. Green JM, Thomas S, Sabino J, Howard R, Basile P, Dryden S, Crecelius C, Valerio I. Use of Intraoperative Fluorescent Angiography to Assess and Optimize Free Tissue Transfer in Head and Neck Reconstruction. J Oral Maxillofac Surg. 2013;71(1):1-11, 2013.
140. Chatterjee A, Krishnan NM, Phil M, Van Vliet MM, Powell SG, Rosen JM, Ridgway EB. A Comparison of Free Autologous Breast Reconstruction with and without the Use of Laser-Assisted Indocyanine Green Angiography: A Cost-Effectiveness Analysis. Plast. Reconstr. Surg. 131: 693e, 2013.
141. Garvey P, Selber JC, Hobaugh CW, Zhang H, Butler CE, Baumann DP. Abstract – 50 – Tissue expander breast reconstructions experience fewer complications when skin flaps are assessed with laser fluorescent angiography rather than clinical judgement alone. PSRC Abstract Supplement. 131: 5 May 2013.
142. Sood M, Glat P. Potential of the SPY intraoperative perfusion assessment system to reduce ischemic complications in immediate postmastectomy breast reconstruction. Annals of Surgical Innovation and Research. 2013, 7:9 <http://www.asir-journal.com/content/7/1/9>.
143. Newman MI, Jack MC, Samson MC. SPY-Q Analysis Toolkit Values Potentially Predict Mastectomy Flap Necrosis. Annals of Plastic Surgery. Vol 70, Number 5, May 2013.
144. Hinchcliff KM, Yao A, Taub PJ. Laser-Assisted Indocyanine Green Imaging to Assess Perfusion of Scalp Closure in an Infant. The Journal of Craniofacial Surgery. Vol 24, No 6, Nov 2013.
145. Wapnir I, Dua M, Kierny A, Paro J, Morrison D, Kahn D, Meyer S, Gurtner G. Intraoperative Imaging of Nipple Perfusion Patterns and Ischemic Complications in Nipple-Sparing Mastectomies. Ann Surg Oncol. 21:100-106. January 2014.
146. Janes LE, Hui-Chou HG, Matthews JA, Sabino J, Singh DP. Utilization of Near-infrared Indocyanine Green Angiography for Immediate and Delayed Venous Outflow Assessment in Breast Reconstruction: A Case Report. Plast Reconstr Surg Glob Open 2014;2:e100; Published online 28 January 2014.
147. Duggal CS, Madni T, Losken A. An Outcome Analysis of Intraoperative Angiography for Postmastectomy Breast Reconstruction. Aesthetic Surgery Journal 2014 34: 61.
148. Munabi NCO, Olorunnipa OB, Goltsman D, Rohde CH, Ascherman JA. The ability of intra-operative perfusion mapping with laser-assisted indocyanine green angiography to predict mastectomy flap necrosis in breast reconstruction: A prospective trial. J of Plast, Reconstr & Aesthetic Surg (2014).

149. Kanuri A, Liu AS, Guo L. Whom Should We SPY? A Cost Analysis of Laser-Assisted Indocyanine Green Angiography in Prevention of Mastectomy Skin Flap Necrosis during Prosthesis-Based Breast Reconstruction. *Plast Reconstr Surg*. Volume 133, Number 4, 448e-454e. April 2014.
150. Pestana IA, Zenn MR. Correlation between Abdominal Perforator Vessels Identified with Preoperative Computed Tomography Angiography and Intraoperative Fluorescent Angiography in the Microsurgical Breast Reconstruction Patient. *Annals of Plastic Surgery*. Vol 72, Supplement 2, June 2014.
151. Lee LN, Smith DF, Boahene KD, Byrne PJ. Intraoperative Laser-Assisted Indocyanine Green Imaging for Objective Measurement of the Vascular Delay Technique in Locoregional Head and Neck Flaps. *JAMA Facial Plast Surg*. doi:10.1001/jamafacial.2014.106 Published online June 5, 2014.
152. Wyles CC, Taunton MJ, Jacobson SR, Tran NV, Sierra RJ, Trousdale RT. Intraoperative Angiography Provides Objective Assessment of Skin Perfusion in Complex Knee Reconstruction. *Clinical Orthopaedics and Related Research®*. Published online July 9, 2014.
153. Fourman MS, Phillips BT, Fritz JR, Conkling N, McClain SA, Simon M, Dagum AB. Laser-Assisted Indocyanine Green Dye Angiography Accurately Predicts the Split-Thickness Graft Timing of Integra Artificial Dermis. *Annals of Plastic Surgery*. Vol 73, No 2, August 2014.
154. Phillips BT, Fourman MS, Rivara A, Dagum AB, Huston TL, Ganz JC, Bui DT, Khan SU. Comparing Quantitative Values of Two Generations of Laser-Assisted Indocyanine Green Dye Angiography Systems: Can We Predict Necrosis? *ePlasty*. Vol 14: 367-377. December 5, 2014.
155. Monahan J, Hwang BH, Kennedy JM, Chen W, Nguyen GK, Schooler WG, Wong AK. Determination of a Perfusion Threshold in Experimental Perforator Flap Surgery Using Indocyanine Green Angiography. *Ann Plast Surg* 2014; 73: 602-606.
156. Popiel B, Gupta D, Misra S. Value of an intraoperative real time tissue perfusion assessment system following a nipple-sparing radical mastectomy for advanced breast cancer. *International Journal of Surgery Case Reports* 5 (2014) 30-33.
157. Green JM, Sabino J, Fleming M, Valerio I. Intraoperative Fluorescence Angiography: A Review of Applications and Outcomes in War-Related Trauma. *Military Medicine*, Vol. 180, March Supplement 2015.
158. Valerio I, Green JM, Sacks JM, Thomas S, Sabino J, Acaturk TO. Vascularized Osseous Flaps and Assessing Their Bipartate Perfusion Pattern via Intraoperative Fluorescence Angiography. *J Reconstr Microsurg* 2015;31:45-53.
159. Taylor SR, Jorgensen JB. Use of Fluorescent Angiography to Assess Donor Site Perfusion Prior to Free Tissue Transfer. *The Laryngoscope*. 2015.
160. Hagopian TM, Ghareeb PA, Arslanian BH, Moosavi BL, Carlson GW. Case Report – Breast Necrosis Secondary to Vasopressor Extravasation: Management Using Indocyanine Green Angiography and Omental Flap Closure. *The Breast Journal*. 2015 1-4.
161. Casey WJ, Connolly KA, Nanda A, Rebecca AM, Perdakis G, Smith AA. Indocyanine Green Laser Angiography Improves Deep Inferior Epigastric Perforator Flap Outcomes following Abdominal Suction Lipectomy. *Plastic and Reconstructive Surgery*. Vol 135, No 3, March 2015.
162. Surowitz JB, Most SP. Use of Laser-Assisted Indocyanine Green Angiography for Early Division of the Forehead Flap Pedicle. *JAMA Facial Plastic Surgery*. Published online April 2015.
163. Dua MM, Bertoni DM, Nguyen D, Meyer S, Gurther GC, Wapnir IL. Using intraoperative laser angiography to safeguard nipple perfusion in nipple-sparing mastectomies. *Gland Surgery* 2015.
164. Harless C, Jacobson SR. Current strategies with 2-staged prosthetic breast reconstruction. *Gland Surgery*, Vol 4, No 3 June 2015.
165. Fourman MS, Gersch RP, Phillips BT, Nasser A, Rivara A, Verma R, Dagum AB, Rosengart TK, Bui DT. Comparison of Laser Doppler and Laser-Assisted Indocyanine Green Angiography Prediction of Flap Survival in a Novel Modification of the McFarlane Flap. *Annals of Plastic Surgery*. Vol 75, No 1, July 2015.
166. Beckler AD, Ezzat WH, Seth R, Nabill V, Blackwell KE. Assessment of Fibula Flap Skin Perfusion in Patients Undergoing Oromandibular Reconstruction – Comparison of Clinical Findings, Fluorescein, and Indocyanine Green Angiography. *JAMA Facial Plast Surg*. Published online September 3, 2015.
167. Ducic Y. Intraoperative free Flap Monitoring Using Indocyanine Green. *JAMA Facial Plastic Surgery*. Published online September 3, 2015.
168. Phillips BT, Munabi NCO, Roeder RA, Ascherman JA, Guo L, Zenn MR. The Role of Intraoperative Perfusion Assessment: What is the Current State and How Can I Use It in My

Practice? Plastic and Reconstructive Surgery. February 2016.

169. Harless CA, Jacobson SR. Tailoring through Technology: A Retrospective Review of a Single Surgeon's Experience with Implant-Based Breast Reconstruction before and after Implementation of Laser-Assisted Indocyanine Green Angiography. *The Breast Journal*, 2016 1-8.
170. Zenn MR. Indocyanine Green/SPY Imaging in Perforator Flap Breast Reconstruction. Levine JL, et al. *Perforator Flaps for Breast Reconstruction*. pp. 133-140. 2016 Thieme Medical Publishers, Inc.
171. Griffiths M, Chae MP, Rozen WM. Indocyanine green-based fluorescent angiography in breast reconstruction. *Gland Surg* 2016;5(2):133-149.
172. Chang EI, Kronowitz SJ. Dual-Pedicle Flap for Unilateral Autologous Breast Reconstruction Revisited: Evolution and Optimization of Flap Design over 15 Years. *Plastic and Reconstructive Surgery*, Vol 137, No 5. May 2016.
173. Bertoni DM, Nguyen D, Rochlin D, Hernandez-Boussard T, Meyer S, Choy N, Gurtner GC, Wapnir IL. Protecting Nipple Perfusion by Devascularization and Surgical Delay in Patients at Risk for Ischemic Complications During Nipple-Sparing Mastectomies. *Annals of Surgical Oncology*. Published Online April 2016.
174. Ludolph I, Arkudas A, Schmitz M, Boos AM, Taeger CD, Rother U, Horch RE, Beier JP. Cracking the perfusion code?: Laser-assisted Indocyanine Green angiography and combined laser Doppler spectrophotometry for intraoperative evaluation of tissue perfusion in autologous breast reconstruction with DIEP or ms-TRAM flaps. *Journal of Plastic, Reconstructive & Aesthetic Surgery*. 69, 1382-1388, 2016. doi:10.1016/j.bjps.2016.07.014.
175. Nahabedian MY. Implant-Based Breast Reconstruction: Strategies to Achieve Optimal Outcomes and Minimize Complications. *Journal of Surgical Oncology* 2016; 113:895-905.
176. Martins DB, Farias-Eisner G, Mandelbaum RS, Hoang H, Bradley JP, Lee JC. Intraoperative Indocyanine Green Laser Angiography in Pediatric Autologous Ear Reconstruction. *PRS Global Open*. 2016.
177. Diep GK, Ching Hui JY, Marmor S, Cunningham BL, Choudry U, Portschy PR, Tuttle TM. Postmastectomy Reconstruction Outcomes After Intraoperative Evaluation with Indocyanine Green Angiography Versus Clinical Assessment. *Ann Surg Oncol*. Published online July 2016.
178. Mattison GL, Lewis PG, Gupta SC, Kim HY. SPY Imaging Use in Postmastectomy Breast Reconstruction Patients: Preventative or Overly Conservative? *Plastic and Reconstructive Surgery*. July 2016.
179. Maxwell AK, Deleyiannis F W-B, MPhil. Utility of Indocyanine Green Angiography in Arterial Selection during Free Flap Harvest in Patients with Severe Peripheral Vascular Disease. *PRS Global Open*. Published online October 2016. Open Access. DOI:10.1097/GOX.0000000000001097

## Surgical Oncology

180. Phillips BT, Jain V, Conkling BA, Pameijer C. Abstract - Sentinel lymph Node detection using laser-assisted indocyanine green dye lymphangiography in melanoma & breast cancer patients. 2011 ASCO Annual Mtg. Citation: *J Clin Oncol* 29: 2011 (suppl; abstr 8587).
181. Heath CH, Deep NL, Sweeny L, Zinn KR, Rosenthal EL. Use of Panitumumab-IRDye800 to Image Microscopic Head and Neck Cancer in an Orthotopic Surgical Model. *Ann Surg Oncol*. Published online 2012 Jun 6.
182. Hara H, Mihara M, Seki Y, Todokoro T, Iida T, Koshima I. Comparison of Indocyanine Green Lymphographic Findings with the Conditions of Collecting Lymphatic Vessels of Limbs in Patients with Lymphedema. *Plastic and Reconstructive Surgery*. Vol 132, No 6, Dec 2013.
183. Jain V, Phillips BT, Conkling N, Pameijer C. Sentinel Lymph Node Detection Using Laser-Assisted Indocyanine Green Dye Lymphangiography in Patients with Melanoma. *Int J Surg Oncol*. 2013; 2013: 904214. Published online Dec 8, 2013.
184. Xiong L, Gazyakan E, Yang W, Engel H, Hunerbein M, Kneser U, Hirche C. Indocyanine green fluorescence-guided sentinel node biopsy: A meta-analysis on detection rate and diagnostic performance. *Eur J Surg Oncol* 40 (2014) 843-849.
185. Korn JM, Tellez-Diaz A, Bartz-Kurycki M, Gastman B. Indocyanine Green SPY Elite-Assisted Sentinel Lymph Node Biopsy in Cutaneous Melanoma. *Plast Reconstr Surg*. Volume 133, Number 4, 914-922. April 2014.
186. Liss MA, Farchshchi-Heydari S, Qin Z, Hickey SA, Hall, DJ, Kane CJ, Vera DR. Preclinical Evaluation of Robotic-Assisted Sentinel Lymph Node Fluorescence Imaging. *J Nucl Med*.

Published online July 14, 2014.

187. Cloyd JM, Wapnir IL, Read BM, Swetter S, Greco RS. Indocyanine Green and Fluorescence Lymphangiography for Sentinel Lymph Node Identification in Cutaneous Melanoma. *J. Surg. Oncol.* 2014.
188. Maddox JS, Sabino JM, Buckingham EB, Munding GS, Zelken JA, Bluebond-Langner RO, Singh DP, Holton III LH. Utility of Indocyanine Green Fluorescence Lymphography in Identifying the Source of Persistent Groin Lymphorrhea. *PRS Global Open.* 2014.
189. Dayan JH, Dayan E, Smith ML. Reverse Lymphatic Mapping: A New Technique for Maximizing Safety in Vascularized Lymph Node Transfer. *Plast Reconstr Surg.* Vol 135, No 1, January 2015.
190. Rosenthal EL, Warram JM, Bland, KI, Zinn KR. The Status of Contemporary Image-Guided Modalities in Oncologic Surgery. *Ann Surg* 2015; 261: 46-55.
191. Daskalaki D, Aguilera F, PattonK, Giulianoti PC. Fluorescence in Robotic Surgery. *J Surg Oncol* 2015;9999:1-7.
192. Zelken JA, Tufaro AP. Current Trends and Emerging Future of Indocyanine Green Usage in Surgery and Oncology: An Update. *Ann Surg Oncol.* Published online: 21 July 2015.
193. KleinJan GH, van den Berg NS, de Jong J, Wit EM, Thygessen H, Vegt E, van der Poel HG, van Leeuwen FWB. Multimodal hybrid imaging agents for sentinel node mapping as a means to (re)connect nuclear medicine to advances made in robot-assisted surgery. *Eur J Nucl Med Mol Imaging.* Published online: 15 January 2016.
194. Herrera-Almario G, Patane M, Sarkaria I, Strong VE. Initial Report of Near-Infrared Fluorescence Imaging as an Intraoperative Adjunct for Lymph Node Harvesting During Robot-Assisted Laparoscopic Gastrectomy. *Journal of Surgical Oncology.* Published Online 2016.
195. Shih HB, Shakir A, Nguyen DH. Use of Indocyanine Green-SPY Angiography for Tracking Lymphatic Recovery After Lymphaticovenous Anastomosis. *Annals of Plastic Surgery.* Vol 76, Supp 3, May 2016.

## Urology

196. Tobis S, Knopf J, Silvers C, Yao J, Rashid H, Wu G, and Golijanin D. Near Infrared Fluorescence Imaging With Robotic Assisted Laparoscopic Partial Nephrectomy: Initial Clinical Experience for Renal Cortical Tumors. *The Journal of Urology.* Vol. 186, 47-52, July 2011.
197. Tobis S, Knopf J, Silvers C, Marshall J, Cardin A, Wood R, Reeded J, Erturk E, Madeb R, Yao J, Singer E, Rashid H, Wu G, Messing E, Golijanin D. Near Infrared Fluorescence Imaging After Intravenous Indocyanine Green: Initial Clinical Experience With Open Partial Nephrectomy for Renal Cortical Tumors. *Urology.* 79:958-964.
198. Tobis S, Knopf J, Silvers C, Messing E, Yao J, Rashid H, Wu G, Golijanin D. Robot-Assisted and Laparoscopic Partial Nephrectomy with Near Infrared Fluorescence Imaging. *Journal of Endourology.* Volume 26, July 2012.
199. Borofsky MS, Gill IS, Hemal AK, Marien TP, Jayaratna I, Krane LS, Stifelman MD. Near-infrared fluorescence imaging to facilitate super-selective arterial clamping during zeroischaemia robotic partial nephrectomy. *BJU Int.* 2012 Dec 17. doi: 10.1111/j.1464-410X.2012.11490.x.
200. Manny TB, Patel M, Hemal AK. Fluorescence-enhanced Robotic Radical Prostatectomy Using Real-time Lymphangiography and Tissue Marking with Percutaneous Injection of Unconjugated Indocyanine Green: The Initial Clinical Experience in 50 Patients. *European Urology.* Published online November 2013.
201. Lee Z, Simhan J, Parker DC, Reilly C, Llukani E, Lee DI, Mydlo JH, Eun DD. Novel Use of Indocyanine Green for Intraoperative, Real-time Localization of Ureteral Stenosis During Robot-assisted Ureteroureterostomy. *Urology* 82 (3), 2013.
202. Manny TB, Hemal AK. Fluorescence-enhanced Robotic Radical Cystectomy Using Unconjugated Indocyanine Green for Pelvic Lymphangiography, Tumor Marking, and Mesenteric Angiography: The Initial Clinical Experience. *Urology* (4) 83: 824-830, 2014.
203. McClintock TR, Bjurlin MA, Wysock JS, Borofsky MS, Marien TP, Okoro C, Stifelman MD. Can Selective Arterial Clamping With Fluorescence Imaging Preserve Kidney Function During Robotic Partial Nephrectomy? *Urology* 2014 August; 84(2): 327-332.
204. Siddighi S, Yune JJ, Hardesty J. Indocyanine green for intraoperative localization of ureter. *Am J Obstet Gynecol* 2014; 211:436.e1-2.
205. Bjurlin MA, McClintock TR, Stifelman MD. Near-Infrared Fluorescence Imaging with Intraoperative Administration of Indocyanine Green for Robotic Partial Nephrectomy. *Curr Urol*

Rep (2015) 16:20.

206. Lee Z, Moore B, Giusto L, Eun DD. Use of Indocyanine Green During Robot-assisted Ureteral Reconstructions. *European Urology* 67 (2015) 291-298.
207. Herz D, DaJusta D, Ching C, McLeod D. Segmental arterial mapping during pediatric robot-assisted laparoscopic heminephrectomy: A descriptive series. *Journal of Pediatric Urology*. 2016.

## Vascular Surgery and Wound Therapy

208. Lepow BD, Perry D, Armstrong D. The Use of SPY Intra-operative Vascular Angiography as a Predictor of Wound Healing. *Podiatry Management* 141-148 August 2011.
209. Perry D, Bharara M, Armstrong, DG, Mills, J. Intraoperative Fluorescence Vascular Angiography: During Tibial Bypass. *Journal of Diabetes Science and Technology*. Volume 6, Issue 1, January 2012.
210. Braun JD, Trinidad-Hernandez M, Perry D, Armstrong DG, Mills JL. Early quantitative evaluation of indocyanine green angiography in patients with critical limb ischemia. *J Vasc Surg* 2013;:-1-6.
211. Ziegler M, Ditslear J, Turner MK, Szotek P. Poster – Intraoperative fluorescence angiography using indocyanine green may predict and may prevent wound complications in complex AWR. AWR conference – Washington DC. June 2013.
212. Schlanger R. Clinical Case Update – Using Fluorescence Angiography to Help Assess Lower Extremity Wounds. *Today's Wound Clinic*. Supplement. 2014.
213. Li WW, Arnold J. Imaging of the Chronic Wound and the Emerging Role of Fluorescence Microangiography. Supplement – *Today's Wound Clinic*. 2014.
214. Brooks D. Perfusion Assessment with the SPY System after Arterial Venous Reversal for Upper Extremity Ischemia. *PRS GO*. 2014.
215. Benitez E, Sumpio BJ, Chin J, Sumpio BE. Contemporary assessment of foot perfusion in patients with critical limb ischemia. *Seminars in Vascular Surgery* 27 (2014) 3-15
216. Fourman MS, Phillips BT, Crawford L, McClain SA, Lin F, Thode Jr HC, Dagum AB, Singer AJ, Clark RA. Indocyanine green dye angiography accurately predicts survival in the zone of ischemia in a burn comb model. *Burns* 40 (2014) 940-946.
217. Dissanaik S, Abdul-Hamed S, Griswold JA. Variations in burn perfusion over time as measured by portable ICG fluorescence: A case series. *Burns & Trauma*. Oct 2014. Vol 2, Issue 4.
218. Guthrie SD, Guthrie BR. Utilizing Indocyanine Green Wound Imaging in the Management of Hyperbaric Therapy. *Today's Wound Clinic*. Oct 2014.
219. Arnold J. Clinical Case Update - Using Fluorescence Microangiography for Timely Assessment of Wound Area Perfusion. Supplement to *Today's Wound Clinic*. 2014.
220. Connolly PH, Meltzer AJ, Spector JA, Schneider DB. Indocyanine green angiography aids in prediction of limb salvage in vascular trauma. *Annals of Vascular Surgery* Vol. 29, No. 7, October 2015.
221. Samies JH, Gehling M, Serena TE, Yaakov RA. Use of a fluorescence angiography system in assessment of lower extremity ulcers in patients with peripheral arterial disease: A review and a look forward *Semin Vasc Surg* 28 (2015) 190-194.
222. Wyles CC, Jacobson SR, Houdek MT, Larson DR, Taunton MJ, Sim FH, Sierra RJ, Trousdale RT. Running Subcuticular Closure Enables the Most Robust Perfusion After TKA: A Randomized Clinical Trial. *Clin Orthop Relat Res*. Vol 474, No 1, January 2016.
223. Colvard B, Itoga NK, Hitchner E, Sun Q, Long B, Lee G, Chandra V, Zhou W. SPY Technology as an adjunctive measure for lower extremity perfusion. *J Vasc Surg* 2016. Article in Press.
224. Anghel EL, Falola RA, Kim PJ. Fluorescence Technology for Point of Care Wound Management. *Surgical Technology International XXVIII*. Advanced Wound Healing. 2016.
225. Joh JH, Park H-C, Han S-A, Ahn HJ. Intraoperative indocyanine green angiography for the objective measurement of blood flow. *Annals of Surgical Treatment and Research* 2016;90(5):279-286.
226. Li WW, Carter MJ, Massiach E, Guthrie SD. Vascular assessment of wound healing: a clinical review. *International Wound Journal*. 2016.

227. Rother U, Lang W, Horch RE, Ludolph I, Meyer A, Regus S, Microcirculation evaluated by intraoperative fluorescence angiography after tibial bypass surgery. *Annals of Vascular Surgery*, Accepted Manuscript (2016). doi: 10.1016/j.avsg.2016.07.084.

## Other

228. Zhou Q, Wood R, Schwarz EM, Wang YJ, Xing L. Near-infrared lymphatic imaging demonstrates the dynamics of lymph flow and lymphangiogenesis during the acute versus chronic phases of arthritis in mice. *Arthritis Rheum*. 2010 Jul;62(7):1881-9.
229. Li J, Zhou Q, Wood RW, Kuzin I, Bottaro A, Ritchlin CT, Xing L, Schwarz EM. CD23(+)/CD21(hi) B-cell translocation and ipsilateral lymph node collapse is associated with asymmetric arthritic flare in TNF-Tg mice. *Arthritis Res Ther*. 2011 Aug 31;13(4):R138.
230. Li J, Ju Y, Bouta EM, Xing L, Wood RW, Kuzin I, Bottaro A, Ritchlin CT, Schwarz EM. Efficacy of B cell depletion therapy on joint flare is associated with increased lymphatic flow. *Arthritis Rheum*. 2012 Sep 22.
231. Levey, K. Use of Fluorescence Imaging Technology to Identify Peritoneal Endometriosis: A Case Report of New Technology. *Surg Laparosc Endosc Percutan Tech*. Volume 24, Number 2, April 2014.
232. Schols RM, Connell NJ, Stassen LPS. Near-Infrared Fluorescence Imaging for Real-Time Intraoperative Anatomical Guidance in Minimally Invasive Surgery: A Systematic Review of the Literature. *World J Surg*. Published online: 19 December 2014.
233. Ziegler M, Ditslear J, Turner MK, Szotek P. Poster - Intraoperative fluorescence angiography using indocyanine green may predict and may prevent wound complications in complex AWR

**NOVADAQ** Technologies Inc.

### Corporate Headquarters

5090 Explorer Drive, Suite 202  
Mississauga, ON L4W 4T9  
T: 1 844 NOVADAQ (668-2327)  
customerservice@novadaq.com

### R&D and Manufacturing Center

8329 Eastlake Drive, Unit 101  
Burnaby, BC V5A 4W2  
T: 1 800 665 2236

[novadaq.com](http://novadaq.com)

© 2017 NOVADAQ Technologies, Inc. NOVADAQ, SPY, SPY ELITE, PINPOINT, LUNA and the square illumination design are registered trademarks of NOVADAQ Technologies, Inc. FIREFLY is a registered trademark of Intuitive Surgical, Inc.